

Ultrasound Assessment of Facial and Neck Aging: A Noninvasive Approach to a Minimally Invasive Treatment

Hassan Nasreddine¹, Yehya Tlaiss^{2*}, Firas Hassan², Reina Ibrahim²

¹Department of Plastic Surgery, Specialized Hospital Haidar and Hajjar, Beirut, Lebanon, ²Department of General Surgery, University of Balamand, Beirut, Lebanon

Abstract

This technical note explores the diagnostic potential of ultrasound in assessing age-related changes in the soft tissues of the lower face and neck, with a primary focus on identifying causes of contour deformities and guiding minimally invasive rejuvenation procedures. Seventeen clinical patients with various age-related soft-tissue changes were subjected to ultrasound assessments, targeting issues such as soft-tissue sagging, supra- and subplatysmal adipose tissue excess, platysma thickness, and localization of ptotic platysma strands. The ultrasound examinations successfully identified specific anatomical features contributing to age-related soft-tissue changes in all 17 patients. This information guided tailored treatment plans, resulting in remarkable esthetic improvements in each case. The discussion emphasizes ultrasound's invaluable role as a diagnostic tool for precisely identifying soft-tissue alterations in the lower face and neck. The noninvasive nature and high spatial resolution of ultrasound make it particularly effective for this purpose. The corrective methods guided by ultrasound findings proved to be minimally invasive and yielded successful outcomes in all cases, promoting high levels of patient satisfaction. The study highlights the underutilization of ultrasound's diagnostic potential in clinical practice and highlights the importance of its incorporation into routine assessments. Ultrasound emerges as a cost-effective, noninvasive, and accessible means of accurately diagnosing age-related soft-tissue changes, empowering clinicians to tailor rejuvenation procedures to each patient's unique needs. The hope is that by emphasizing its utility, this study encourages the broader adoption of ultrasound in clinical practice.

Keywords: Face and neck, noninvasive, plastic surgery, ultrasound

INTRODUCTION

Facial and neck rejuvenation surgeries are highly desirable procedures in the world of cosmetic surgery. These treatments have evolved throughout the years starting with basic skin treatments to more complex procedures that reconstruct various parts of the face.^[1] However, as these surgeries became more advanced, they often left patients with visible scars, required anesthesia, and involved a long recovery period. As technology progressed, some surgeons began to explore less invasive methods to address age-related changes in the face and neck. These minimally invasive techniques, such as liposuction and laser therapy, became popular.^[2] However, some experts questioned their effectiveness and durability.^[3] Their argument was that there must be a clear view of anatomical structures in order to achieve the best results and avoid complications.

The aging process often brings about unwelcome changes in our facial appearance, particularly in the lower third of the face and

neck. These changes can result in sagging skin, the accumulation of fat, and the appearance of wrinkles, significantly impacting one's esthetic appeal. While various methods have been employed to address these issues, the utilization of ultrasound for the diagnosis and treatment of age-related involutive changes in these areas has remained largely unexplored in clinical practice.^[4] Ultrasound technology has emerged as a valuable tool for assessing various aspects of facial anatomy and physiology. Chen *et al.*^[5] utilized shear wave sonoelastography (SWS) to investigate the stiffness of superficial and deep masticatory muscles in patients with orofacial pain, revealing increased stiffness in the ipsilateral masseter muscles, with a similar trend observed in the temporalis muscles. This study highlights the potential of SWS in objectively quantifying muscle alterations associated with orofacial pain. Moreover, Wu *et al.*^[6] emphasized

Address for correspondence: Dr. Yehya Tlaiss,
University of Balamand, Beirut, Lebanon.
E-mail: yehyatlaiss@hotmail.com

Received: 15-12-2023 Revised: 11-02-2024 Accepted: 06-03-2024 Available Online: 28-08-2024

Access this article online

Quick Response Code:



Website:
<https://journals.lww.com/jmut>

DOI:
10.4103/jmu.jmu_175_23

This is an open access journal, and articles are distributed under the terms of the Creative Commons Attribution-NonCommercial-ShareAlike 4.0 License, which allows others to remix, tweak, and build upon the work non-commercially, as long as appropriate credit is given and the new creations are licensed under the identical terms.

For reprints contact: WKHLRPMedknow_reprints@wolterskluwer.com

How to cite this article: Nasreddine H, Tlaiss Y, Hassan F, Ibrahim R. Ultrasound assessment of facial and neck aging: A noninvasive approach to a minimally invasive treatment. J Med Ultrasound 2024;32:244-8.

the importance of high-resolution ultrasound in visualizing facial vascular and neural structures relevant to esthetic injections. Their pictorial essay elucidates the intricate neurovascular networks of the facial and submental regions, offering insights into potential complications and safety considerations during esthetic procedures. By integrating insights from these studies, our technical note aims to accentuate the utility of ultrasound in elucidating facial anatomy and pathology, thereby contributing to a comprehensive understanding of diagnostic and therapeutic approaches in facial medicine while taking account of our modest 17 clinical patients which showed promising results after utilizing ultrasound assessment.

Remarkably, despite its capability to provide detailed anatomical information, ultrasound has not yet been widely used for diagnosing and strategizing treatment approaches for age-related changes in the lower third of the face and neck.^[7]

MATERIALS AND METHODS

The methodology we have developed involves conducting ultrasound assessments with the patient in a vertical position, allowing us to identify the maximum point of soft-tissue sagging in the lower face and chin area without any external compression. Subsequently, we evaluate various tissue parameters, including the presence of excess supra- and subplatysmal adipose tissue, platysma thickness, and the localization of ptotic platysma strands. This approach also considers the composition of tissues causing disruptions in the lower jaw contour.

ULTRASOUND SETTINGS

The two-dimensional ultrasound examinations were conducted using a Philips EPIQ 7G equipped with a linear

transducer (L12-3) operating at a frequency range of 5–12 MHz. The depth was adjusted to 4–6 cm, gain was optimized for tissue contrast, focus was set at 2–4 cm, and dynamic range was adjusted to 50 dB. The author, Dr. Nassreddine, possesses extensive expertise in ultrasound imaging, with over 10 years of clinical experience specializing in diagnostic ultrasound of the head-and-neck region. The study was conducted in accordance with the Declaration of Helsinki and was approved by the Rafic Hariri University Hospital Institutional Review Board, Beirut, Lebanon (approval number: FWA00016432). Written informed consent was obtained from the patients for participation in this study and the publication of the finding.

Ultrasound imaging has shown potential in evaluating soft-tissue structures in the face and neck area. Its high spatial resolution allows for an examination of tissues aiding in the diagnosis of various conditions.

Numerous studies have highlighted the range of applications and effectiveness of ultrasound in imaging face tissues. It has been proven to be accurate and reliable. For example, Almuhanha *et al.* emphasized how ultrasound can accurately assess the severity and activity of inflammatory dermatoses making it a valuable tool for diagnosing skin conditions.^[8] Evirgen and Kamburoğlu recommended using ultrasound-guided core needle biopsy to diagnose cervicofacial masses confirming its reliability for diagnosis.^[9] Additionally, Jacobson *et al.* highlighted that ultrasound is excellent for evaluating masses in soft tissues with its exceptional imaging capabilities.^[10]

It has been used in various conditions and pathologies affecting the neck area well. A study by Akinbami *et al.* highlighted how ultrasound can be useful in diagnosing swellings in the

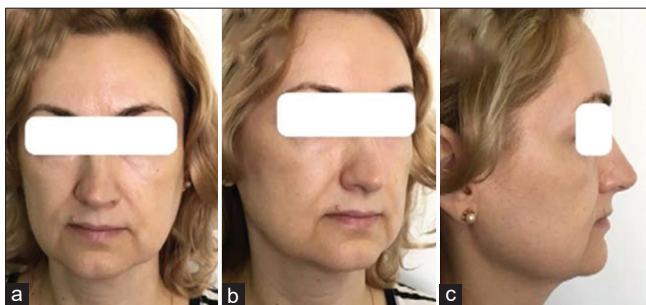

Figure 1: Patient X, 45 years old, before surgery (a-c)

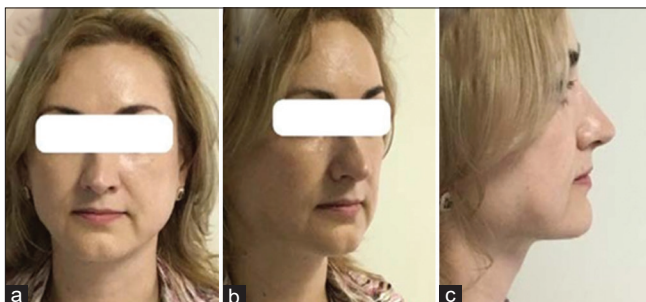

Figure 3: Patient X, 46 years old, 11 months after surgery (a-c)

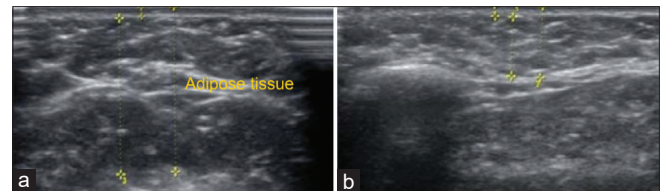


Figure 2: Accumulation of adipose tissue in the chin area (a), along the contour of the lower jaw (b)

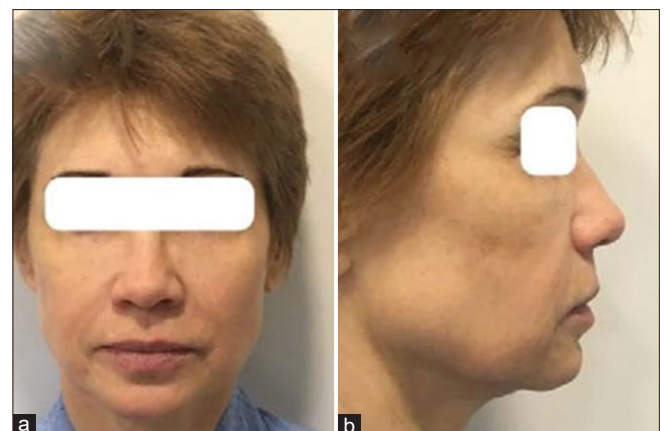


Figure 4: Patient G, 54 years old, before surgery (a and b)

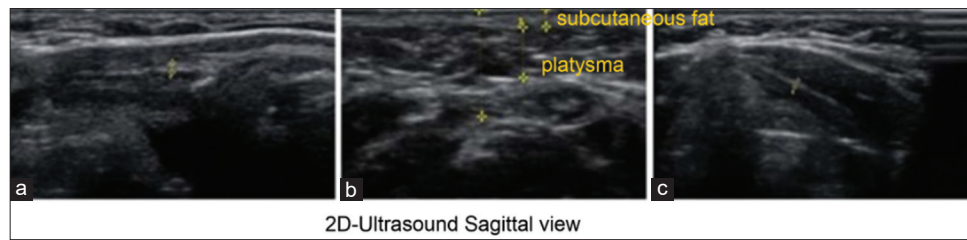


Figure 5: A slight accumulation of adipose tissue along the contour of the lower jaw (a), which did not exceed the thickness of the subcutaneous fat in adjacent areas, in the chin area (b), and ptotic platysma bands (c). 2D: Two-dimensional

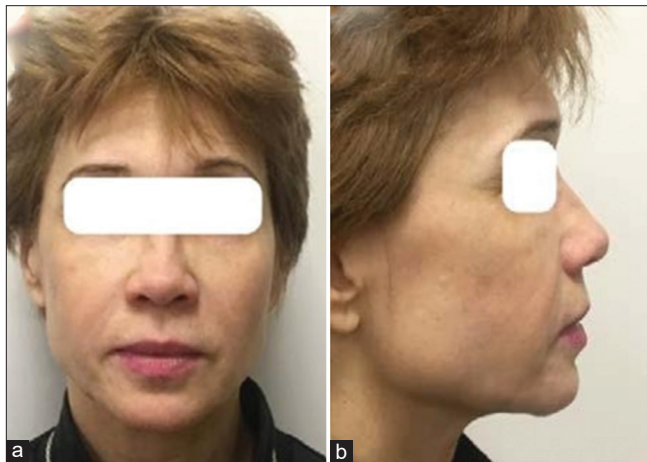


Figure 6: Patient G, 54 years old, 7 months after surgery (a and b)

tissues of the neck emphasizing the accuracy achieved through specific probe features.^[11] Gritzmann *et al.* discussed the role of sonography in guiding needle biopsies of neoplasms and lymph nodes in tissues of the neck demonstrating its importance in assisting with diagnosis and treatment planning.^[12] Additionally, Liu *et al.* emphasized how ultrasonography plays a role in evaluating masses in the head-and-neck region and conducting cancer screenings considering the prominence of tissues, within this anatomical area.^[13]

Ultrasound with high spatial resolution has been used to assess age-related changes in facial soft tissues, enabling noninvasive monitoring and surgical planning.^[14] It allows thorough visualization and evaluation of age-related soft-tissue changes, such as submental fullness in aging necks.^[15] Its efficacy extends to differentiating between various superficial tissue diseases, assisting in the identification of benign and malignant cutaneous malignancies,^[14] and has proven essential in differentiating between a wide range of illnesses and assisting physicians in making prompt decisions.^[16] The noninvasive nature of ultrasound, as well as its real-time imaging and precision, makes it a vital tool for examining complicated soft-tissue structures in the face and neck, further improving clinical evaluation and patient care.

RESULTS

To illustrate the practical application of our approach, let's examine a few clinical cases:

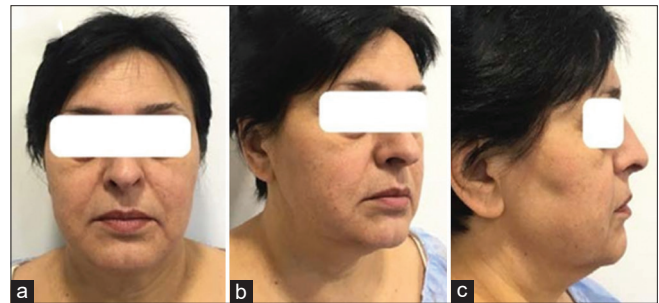

Figure 7: Patient K, 58 years old, before surgery (a-c)

Patient X, aged 45, presented with soft-tissue prolapse in the lower face and neck [Figure 1]. Visual inspection revealed subtle sagging, excess skin, and wrinkles. Ultrasound imaging showed significant adipose tissue accumulation in these areas, suggesting that localized removal of excess subcutaneous fat would suffice to restore esthetic harmony [Figure 2].

Thus, according to the results of ultrasound examination, it became obvious that local removal of excess subcutaneous adipose tissue in the areas of impaired contours of the lower jaw and chin area [Figure 2] is sufficient to restore the correct esthetic lines of these areas, which was confirmed by the results of the patient's treatment [Figure 3].

Patient G, aged 54, exhibited similar symptoms [Figure 4], but ultrasound revealed ptotic platysma strands as the primary cause of the contour disruption [Figure 5]. In this case, a combination of closed platysmotomy and contour liposuction effectively corrected the esthetic issues [Figure 6].

In a number of patients with excessive deposition of subcutaneous fat of the lower third of the face and submental region, the state of platysma and the presence/absence of its ptosis cannot be objectively assessed during examination and physical examination. For example, it is in such patients that the situation is common when liposuction eliminated excess fatty tissue, but the contours of the cervical-chin angle were deformed by platysma bands that became noticeable after the operation or sagging of the entire platysma. In such situations, ultrasound examination was of great benefit, and the study was carried out before liposuction in the lower third of the face, neck, and chin. In the presence of ptotic platysmal bands, their surgical correction was added to the treatment plan.

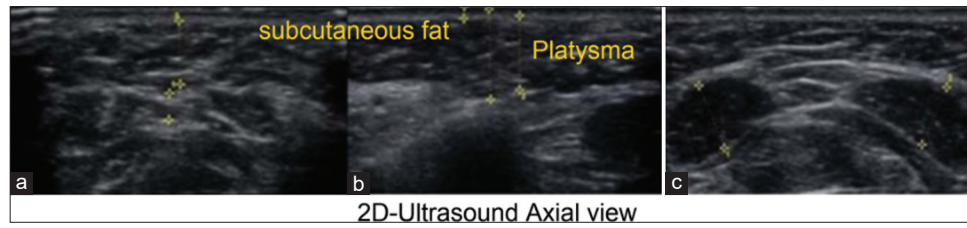

Figure 8: Accumulation of adipose tissue above the platysma (a), along the contour of the lower jaw (b), the presence of ptotic strands of platysma (c). 2D: Two-dimensional

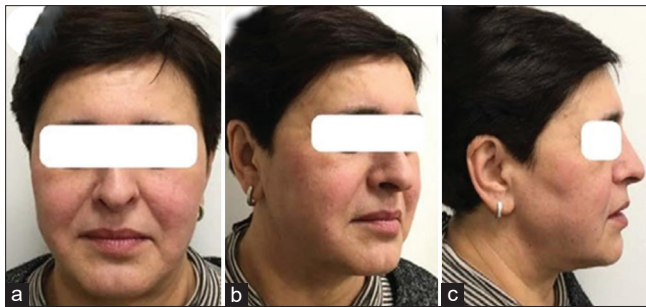

Figure 9: Patient K, 58 years old, 6 months after surgery (a-c)

Patient K, aged 58, displayed sagging and an accumulation of adipose tissue in the chin and neck areas [Figure 7]. Ultrasound guided us to perform liposuction and platysmotomy, addressing both the fatty tissue and ptotic bands of the platysma.

The ultrasound examination revealed an excessive buildup of adipose (fat) tissue above the platysma muscle in the chin and neck areas. This resulted in a distortion of the lower jaw's contour due to fat accumulation. Additionally, ptotic (drooping) medial strands of the platysma muscle were identified [Figure 8], which were not detectable through visual inspection or palpation during the physical examination.

Thus, liposuction and platysmotomy performed under intraoperative ultrasound guidance were sufficient to correct age-related involutive changes in the lower third of the face and neck in this patient [Figure 9].

In certain cases, especially when assessing patients with excessive subcutaneous fat in the lower face and neck, ultrasound becomes invaluable. It allows us to objectively evaluate the state of the platysma and determine the need for its surgical correction.

Through our work, we have recognized the substantial diagnostic value of ultrasound in assessing age-related soft-tissue changes in the lower face and neck. This imaging technique is not only highly effective but also accessible, noninvasive, and comparatively straightforward. It enables us to pinpoint the root causes of contour deformities and determine minimally invasive corrective methods, which have proven successful in treating 17 patients.

DISCUSSION

The clinical cases presented herein vividly exemplify the important role of ultrasound as a diagnostic tool in the

evaluation and treatment planning of age-related soft-tissue changes in the lower face and neck. Our findings demonstrate its practical utility in guiding treatment decisions, hence contributing to the successful resolution of esthetic concerns in our patient cohort.

In the case of Patient X, our ultrasound assessment revealed significant adipose tissue accumulation, which supported the decision to pursue localized fat removal for esthetic enhancement. The correspondence between the ultrasound diagnosis and the treatment outcome underscores the precision and reliability of ultrasound in diagnosing and strategizing minimally invasive interventions [Figures 1-3].^[17]

Similarly, Patient G's case highlighted the significance of ultrasound in identifying ptotic platysma strands as the root cause of contour disruption. This diagnosis led to a tailored approach combining closed platysmotomy and contour liposuction, effectively addressing the underlying issue and achieving satisfactory results [Figures 4-6].^[18]

The utility of ultrasound extended to cases where the state of the platysma could not be reliably determined through physical examination alone. For patients with excessive subcutaneous fat, such as Patient K, ultrasound provided valuable insights into the presence of ptotic platysmal bands. This information guided us to incorporate surgical correction of the platysma into the treatment plan, resulting in improved outcomes [Figures 7-9].^[19]

Our experience with these cases reinforces the value of ultrasound as an objective and reliable means of assessing age-related changes in the lower face and neck. Moreover, it highlights the accessibility, noninvasiveness, and relative simplicity of this imaging technique, making it an invaluable tool in clinical practice.

In future research, a larger and more diverse patient population could provide additional insights into the utility of ultrasound in cosmetic surgery. Moreover, prospective studies may help establish standardized protocols for ultrasound-guided procedures, enhancing their applicability and reproducibility in clinical settings.

In conclusion, ultrasound presents a noninvasive, cost-effective, and readily available tool for accurately diagnosing the specific location and extent of age-related changes in the facial and neck tissues. This information is crucial for planning minimally invasive rejuvenation procedures tailored to each patient's unique needs. Our technical note helps in showcasing this

technique's utility in hopes of encouraging its usage more readily.

Financial support and sponsorship

Nil.

Conflicts of interest

There are no conflicts of interest.

REFERENCES

- Chuang J, Barnes C, Wong BJ. Overview of facial plastic surgery and current developments. *Surg J (N Y)* 2016;2:e17-28.
- de Maio M. The minimal approach: An innovation in facial cosmetic procedures. *Aesthetic Plast Surg* 2004;28:295-300.
- Shome D, van der Hulst RR, Kumar V, Booi DI, Mhatre PD. Evolution and trends of facial plastic surgery and facial aesthetic procedures in India: From awakening to revival. *Aesthet Surg J Open Forum* 2023;5:ojad022.
- Swanson E. The importance of photographic standardization in evaluating microfocused ultrasound facial skin treatments. *Aesthet Surg J* 2017;37:P142-4.
- Chen YJ, Lin HY, Chu CA, Wu WT, Chen LR, Özçakar L, *et al.* Assessing thickness and stiffness of superficial/deep masticatory muscles in orofacial pain: An ultrasound and shear wave elastography study. *Ann Med* 2023;55:2261116. doi:10.1080/07853890.2023.2261116.
- Wu WT, Chang KV, Chang HC, Kuan CH, Chen LR, Mezian K, *et al.* Ultrasound imaging of facial vascular neural structures and relevance to aesthetic injections: A pictorial essay. *Diagnostics (Basel)* 2022;12:1766.
- Li Z, Chi Y, Chen C, Jin L, Huang J, Long X, *et al.* A comprehensive ultrasound evaluation approach of lower facial structure before masseter muscle botulinum toxin injection. *Aesthet Surg J* 2023;43:P283-92.
- Almuhanna N, Wortsman X, Wohlmuth-Wieser I, Kinoshita-Ise M, Alhusayen R. Overview of ultrasound imaging applications in dermatology [Formula: See text]. *J Cutan Med Surg* 2021;25:521-9.
- Evirgen Ş, Kamburoğlu K. Review on the applications of ultrasonography in dentomaxillofacial region. *World J Radiol* 2016;8:50-8.
- Jacobson JA, Middleton WD, Allison SJ, Dahiya N, Lee KS, Levine BD, *et al.* Ultrasonography of superficial soft-tissue masses: Society of radiologists in ultrasound consensus conference statement. *Radiology* 2022;304:18-30.
- Akinbami BO, Ugboko VI, Owotade EJ, Obiechina AE, Adetiloye VO, Ayoola O. Applications of ultrasonography in the diagnosis of soft tissue swellings of the cervicofacial region. *West Afr J Med* 2006;25:110-8.
- Gritzmann N, Hollerweger A, Macheiner P, Rettenbacher T. Sonography of soft tissue masses of the neck. *J Clin Ultrasound* 2002;30:356-73.
- Liu CH, Hsu SY, Wang CP. Ultrasound examinations of the head and neck – From the beginning to now. *J Med Ultrasound* 2020;28:5-6.
- Alimova S, Sharobaro V, Yukhno A, Bondarenko E. Possibilities of ultrasound examination in the assessment of age-related changes in the soft tissues of the face and neck: A review. *Appl Sci* 2023;13:1128.
- Sharobaro V, Alimova S, Telnova A, Shamanaeva L. Ultrasound diagnosis of age-related involutional changes in the lower third of face and neck to determine treatment techniques. *Pak J Med Sci* 2021;37:272-6.
- Catalano O, Varelli C, Sbordone C, Corvino A, De Rosa D, Vallone G, *et al.* A bump: What to do next? Ultrasound imaging of superficial soft-tissue palpable lesions. *J Ultrasound* 2020;23:287-300.
- Humby F, Kelly S, Bugatti S, Manzo A, Filer A, Mahto A, *et al.* Evaluation of minimally invasive, ultrasound-guided synovial biopsy techniques by the OMERACT filter – Determining validation requirements. *J Rheumatol* 2016;43:208-13.
- Mashkevich G, Wang J, Rawnsley J, Keller GS. The utility of ultrasound in the evaluation of submental fullness in aging necks. *Arch Facial Plast Surg* 2009;11:240-5.
- Connell BF. Cervical lift: Surgical correction of fat contour problems combined with full-width platysma muscle flaps. *Aesthetic Plast Surg* 1976;1:355-62.